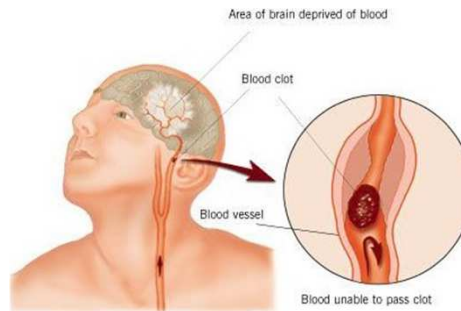
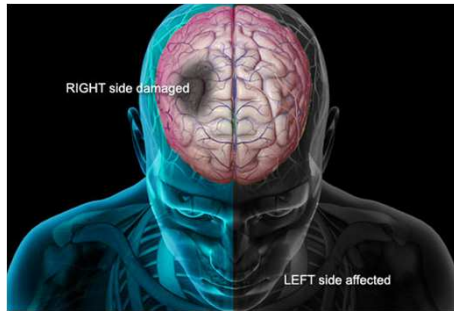
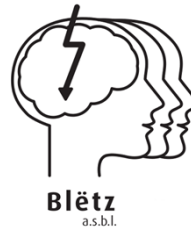

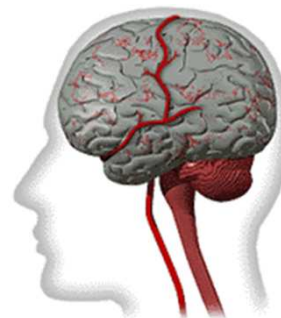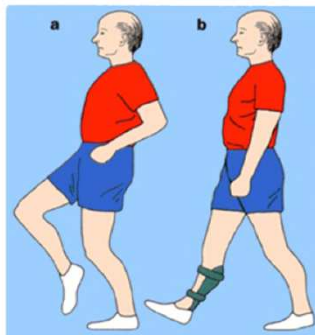
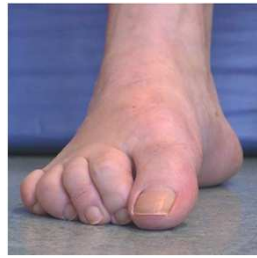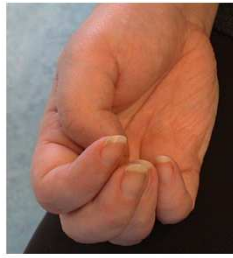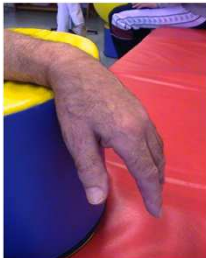La journée de l'AVC

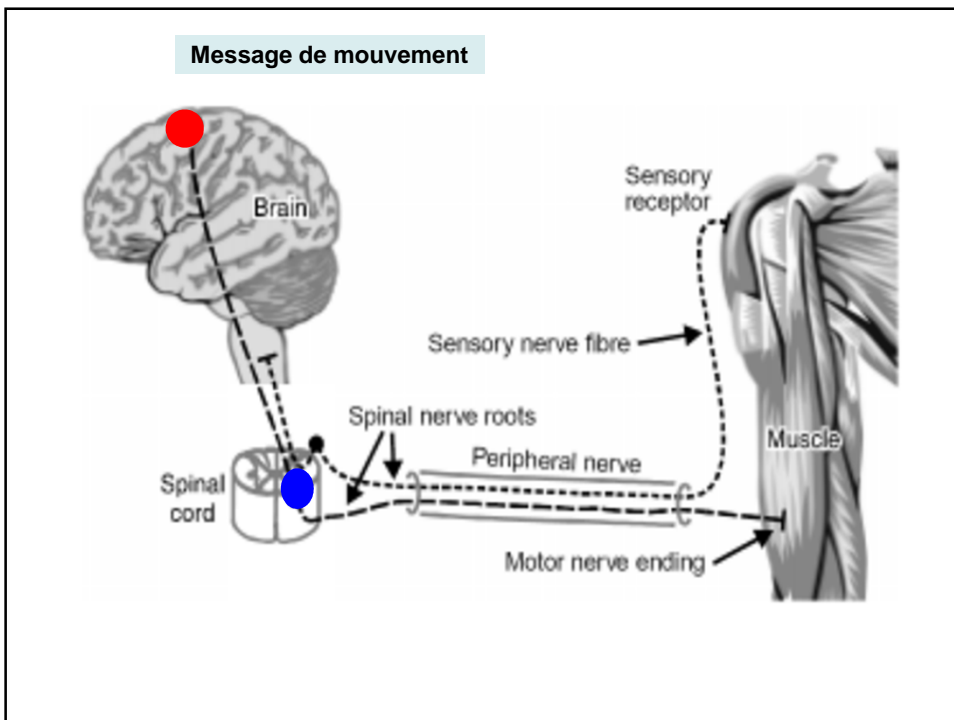
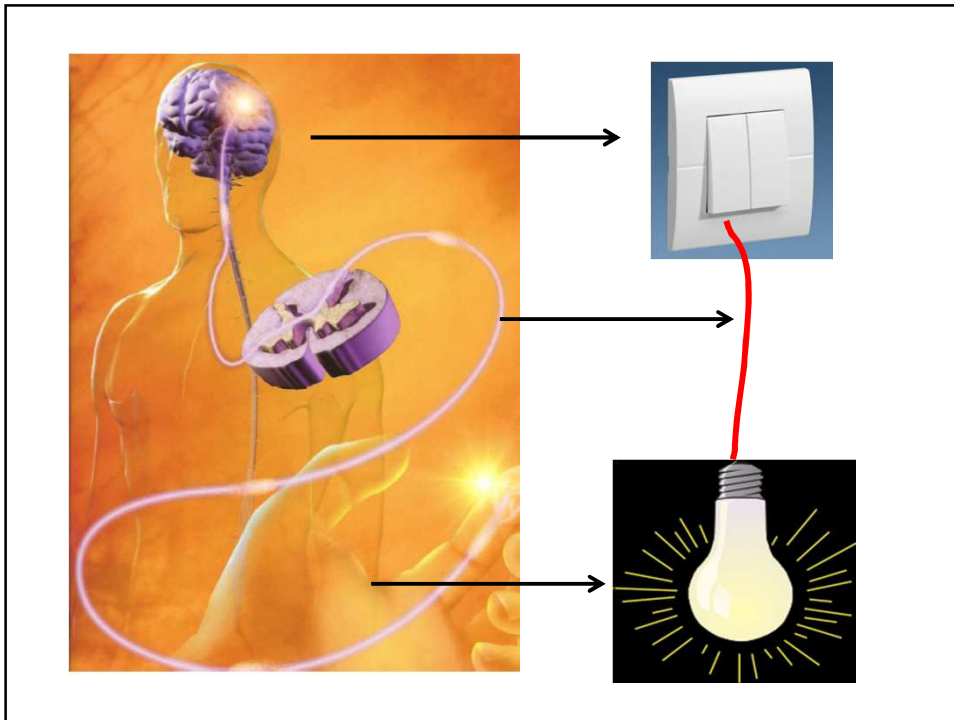


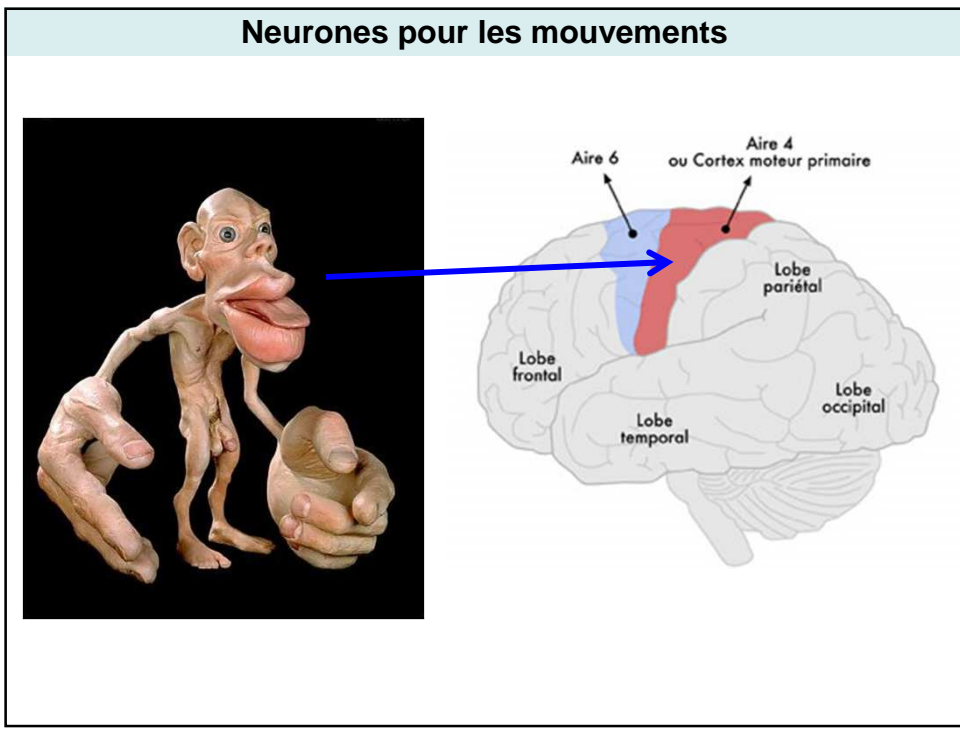
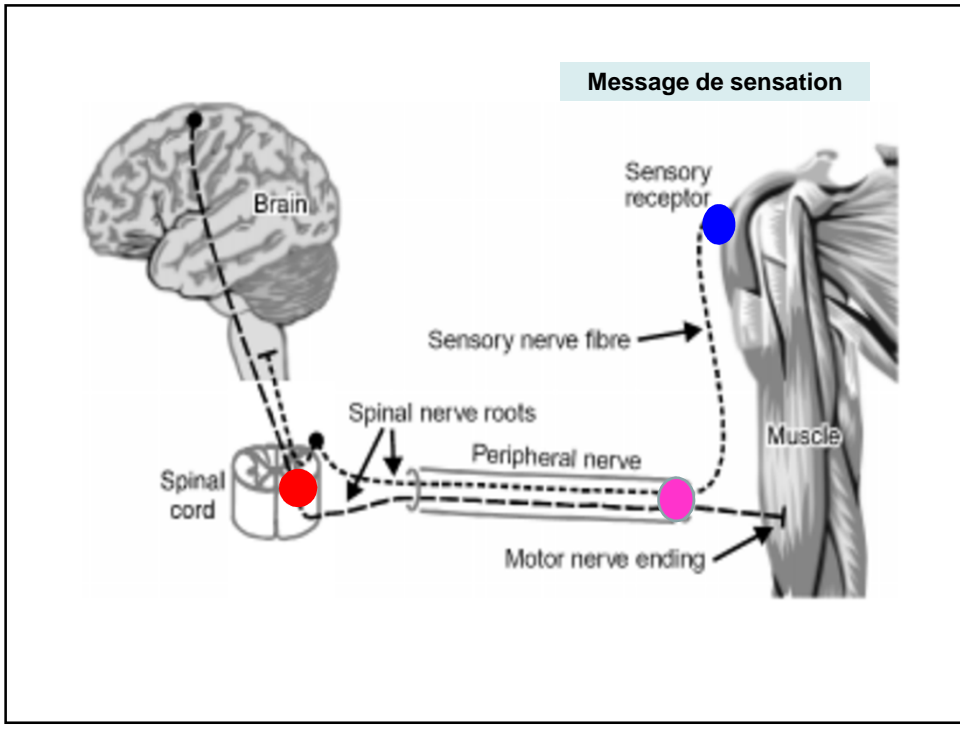
Delire Ralph



Accident vasculaire cérébral= population hétérogène







Neurones pour les mouvements

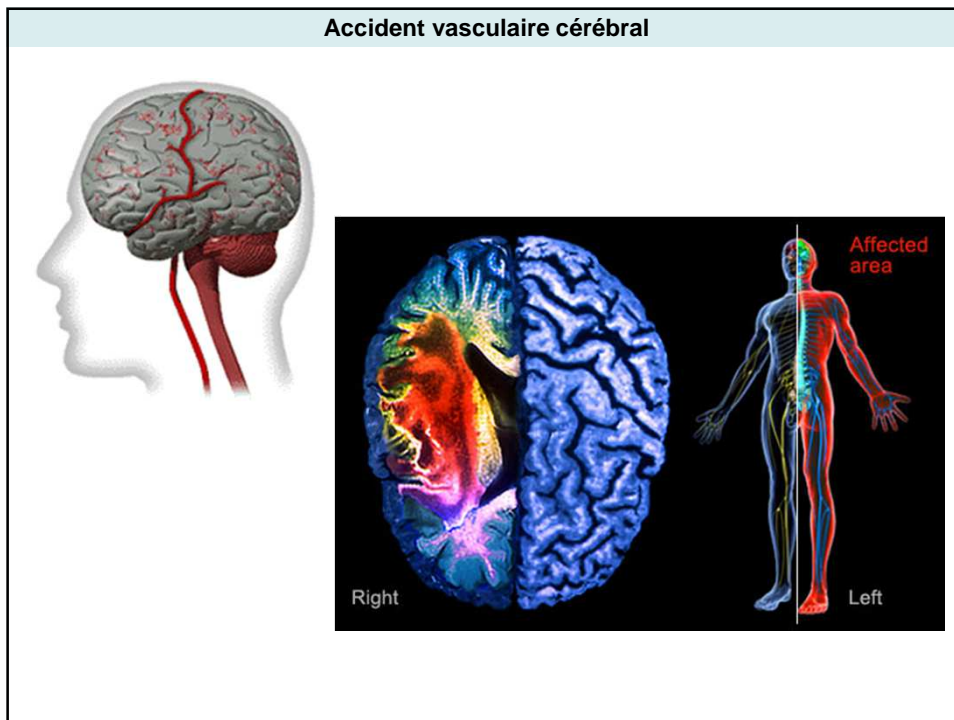
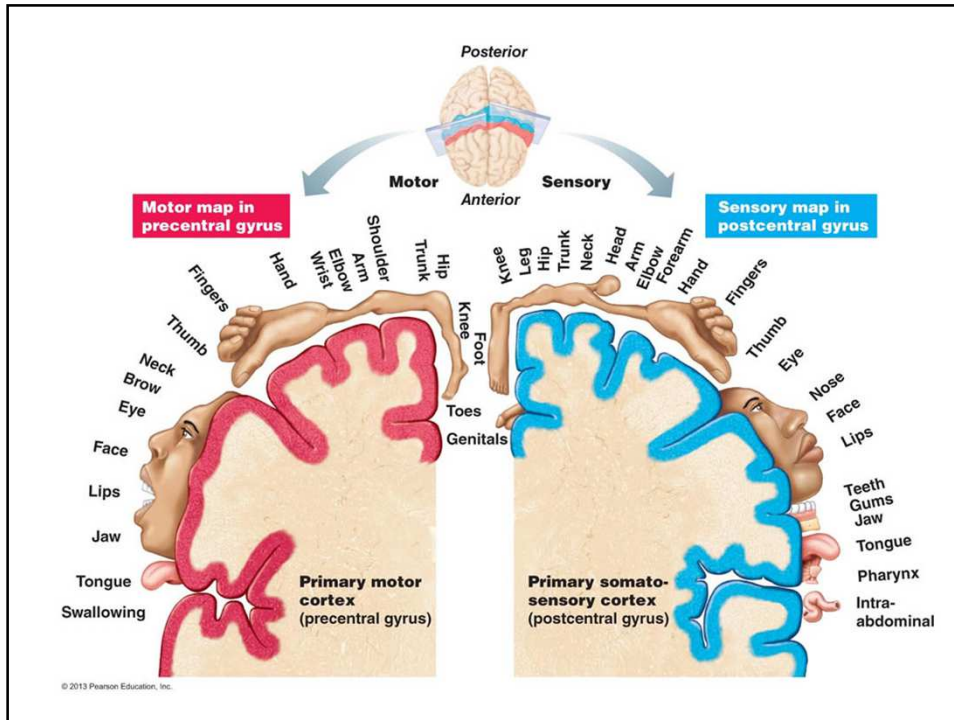
The diagram illustrates the motor cortex with labels for 'Aire 6 ou Cortex moteur primaire' and 'Aire 4'. It also identifies the 'Lobe frontal', 'Lobe pariétal', 'Lobe temporal', and 'Lobe occipital'. A blue arrow points from the brain to a homunculus map of the motor cortex, where the size of each body part represents its cortical representation. A small photograph of a hand is also included.

© BrainConnection.com

Neurones pour les sensations

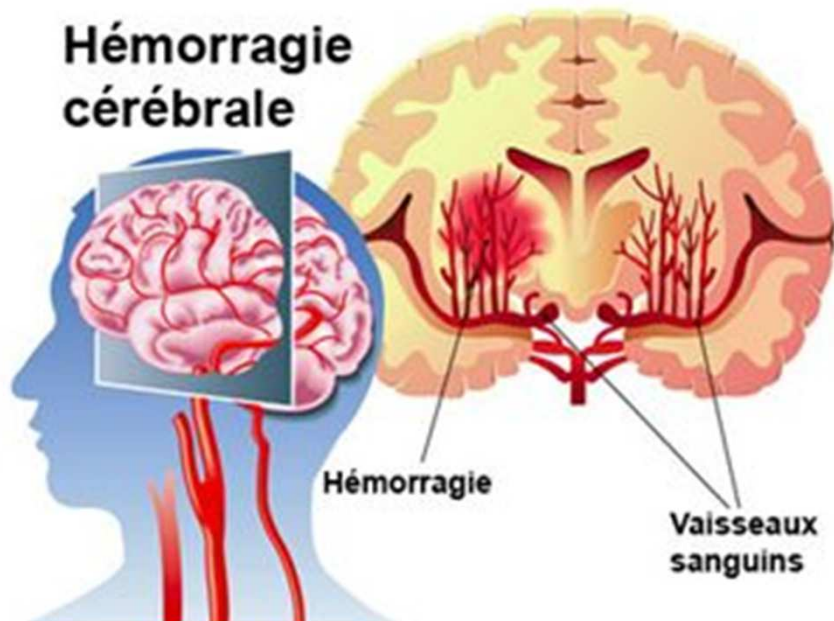
Scissure de Rolando (sillon central)
Cortex somato-sensoriel

The diagram shows the somatosensory cortex with a homunculus map. Labels include: 'Tête', 'Cou', 'Épaule', 'Bras', 'Main', 'Doigt', 'Pouce', 'Yeux', 'Nez', 'Face', 'Lèvres', 'Mâchoire', 'Langue', 'Gorge', 'Tronc', 'Jambe', 'Pied', 'Orteils', and 'Organes génitaux'. A section is labeled 'Représentation en coupe'.

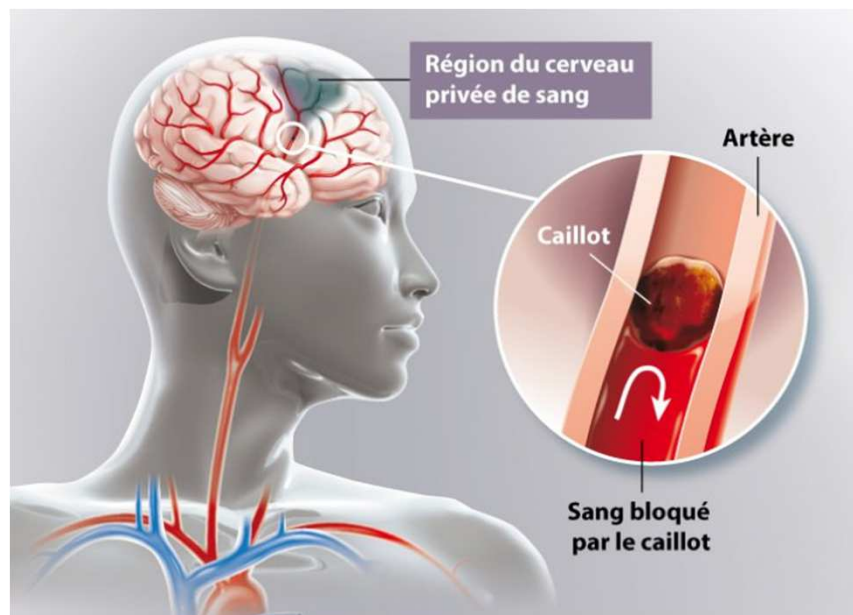


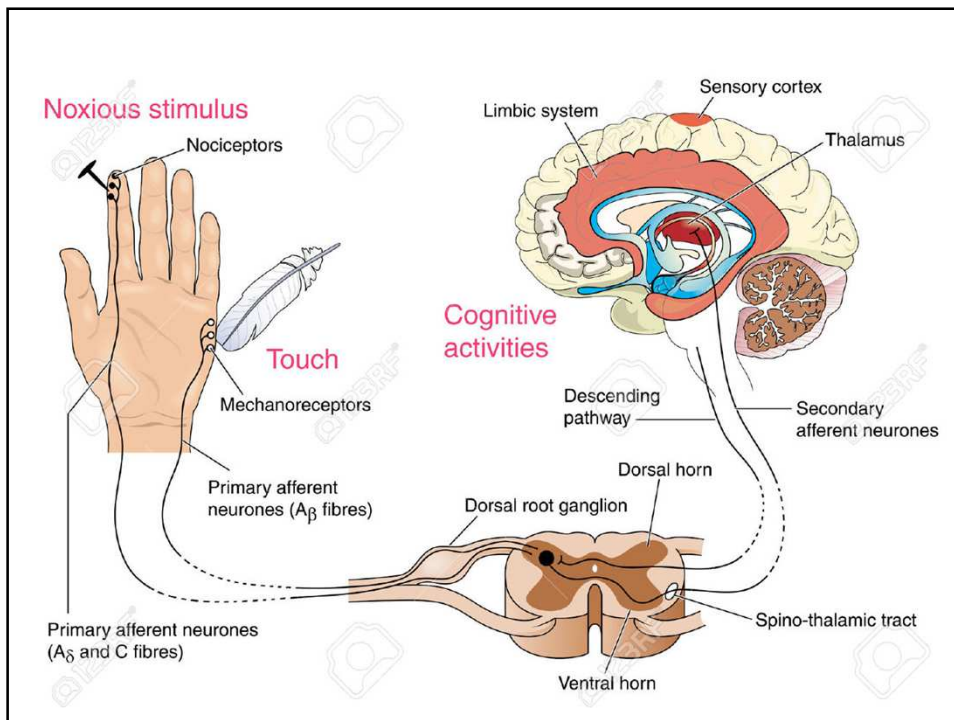
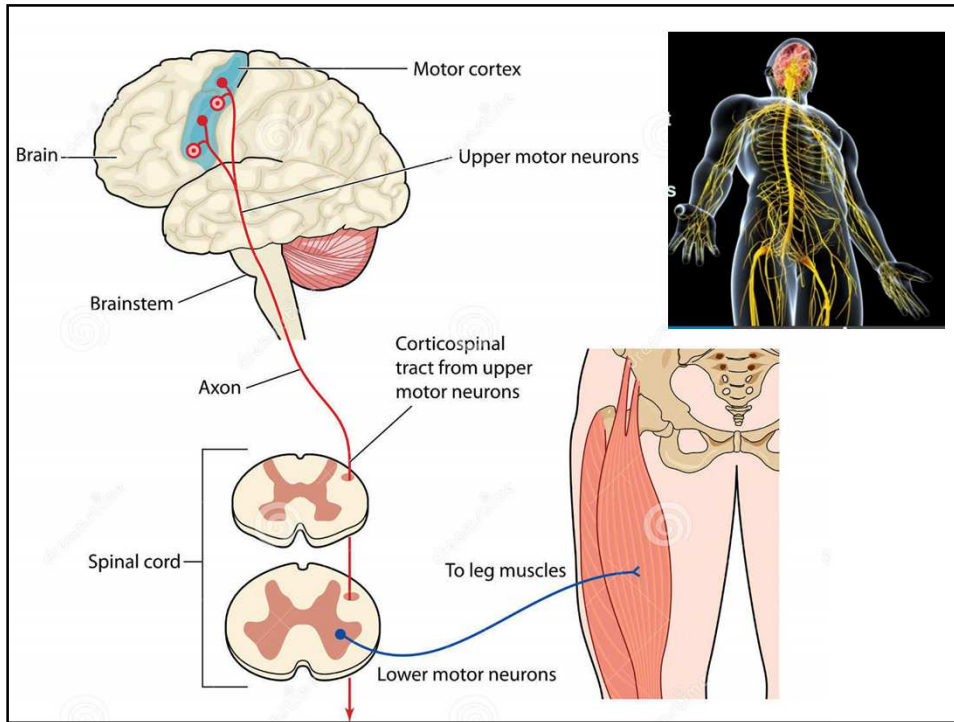
Différents types d'AVC : ischémique ou hémorragique

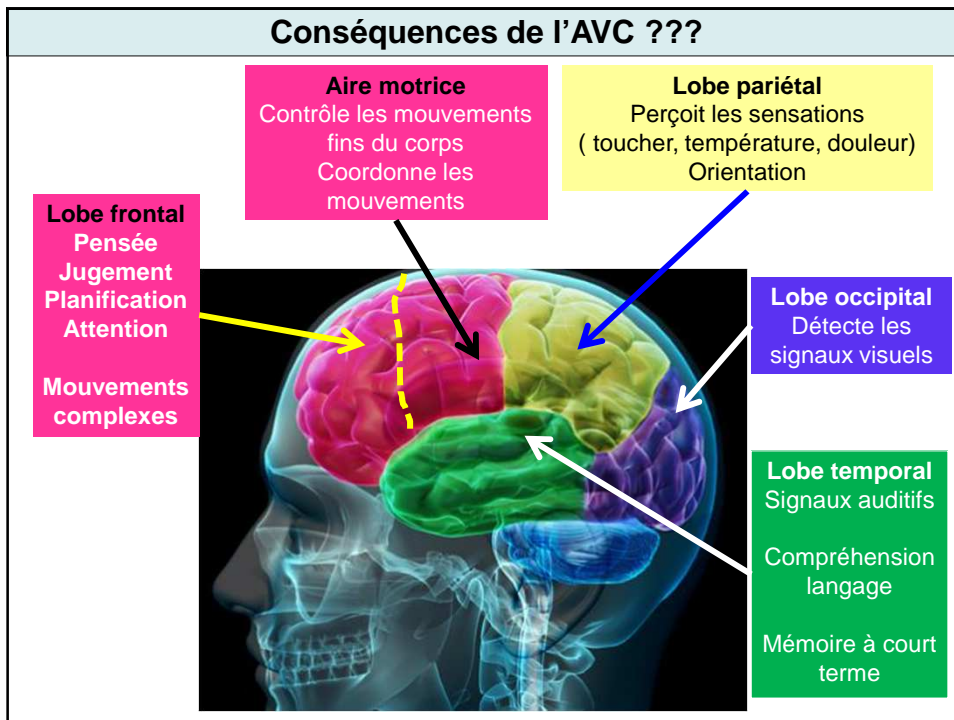
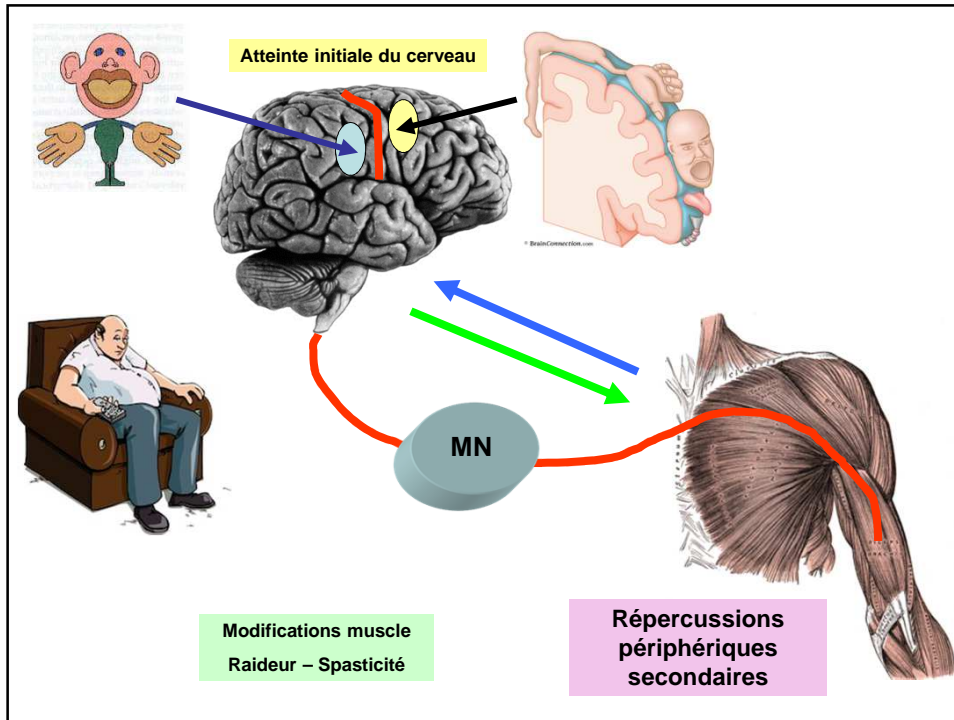
Hémorragie cérébrale

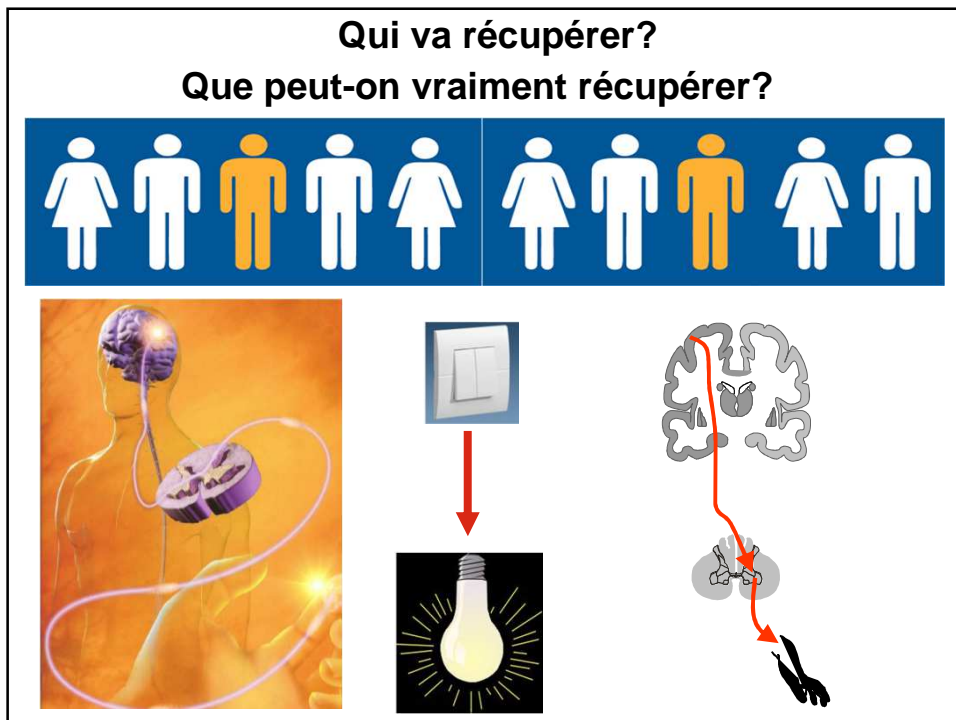
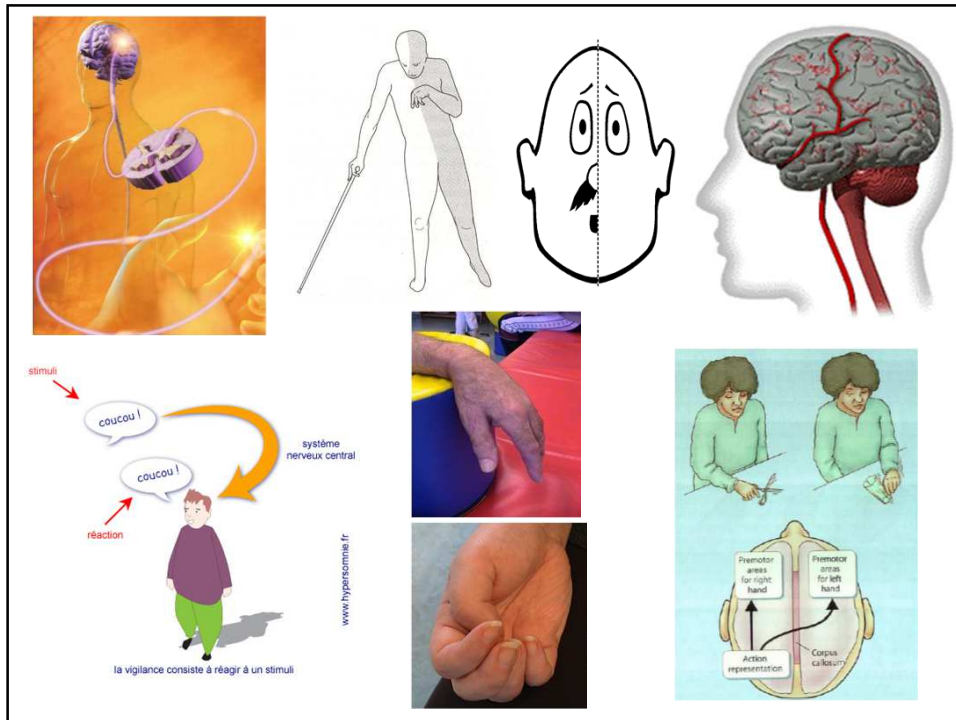


Différents types d'AVC : ischémique ou hémorragique





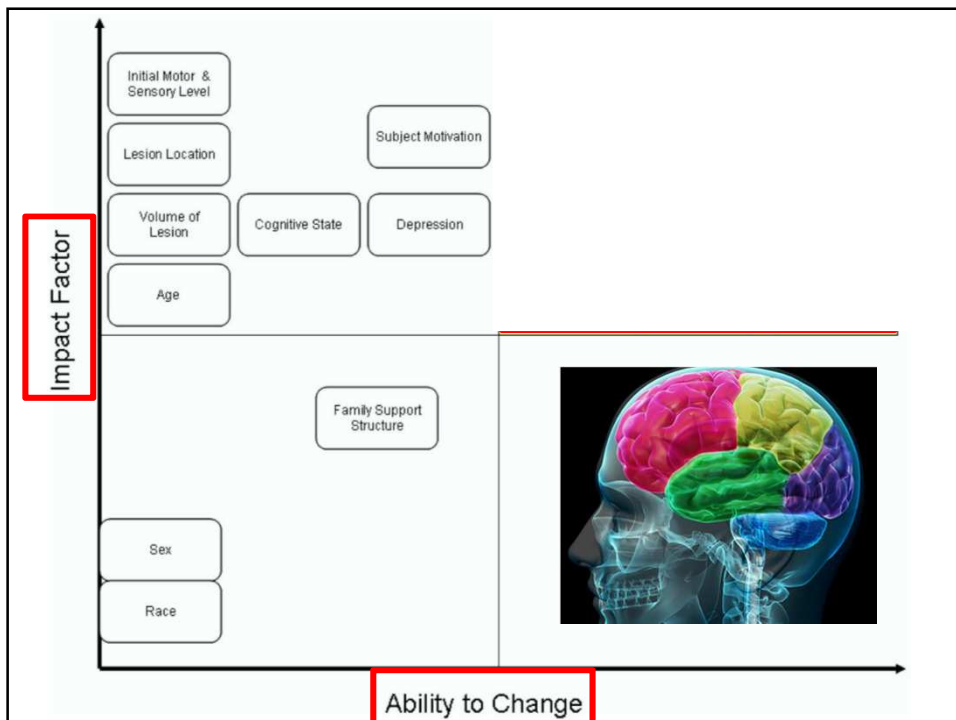
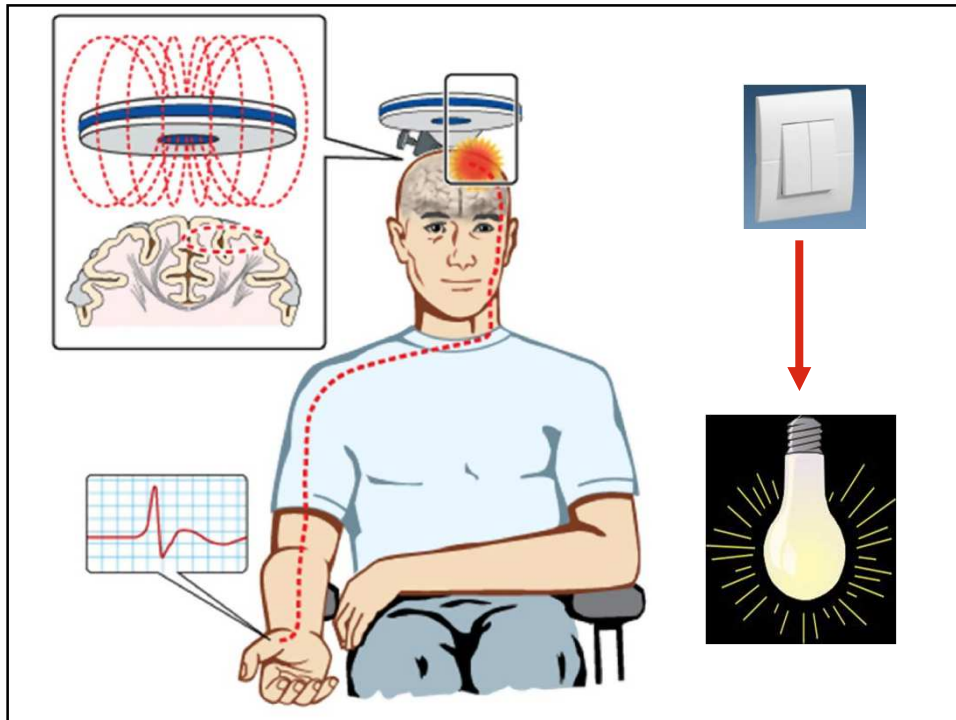






**Age de la maison
Localisation de l'incendie
Qualité des matériaux**


**Age du sujet
Localisation de la lésion
Capacités motrices et
sensitives du sujet**



Contenu de la séance de rééducation

Passives

Absence de participation active



Séance de rééducation


0 100 %

Passif <<< actif

Passif

Actif


0 100 %



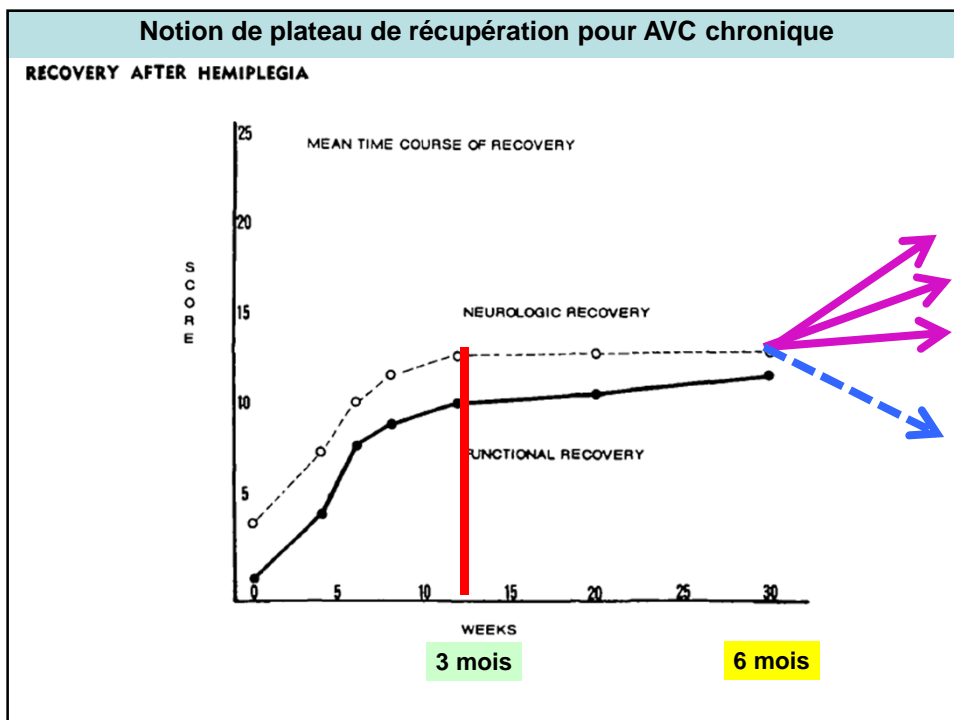
Activo-passives

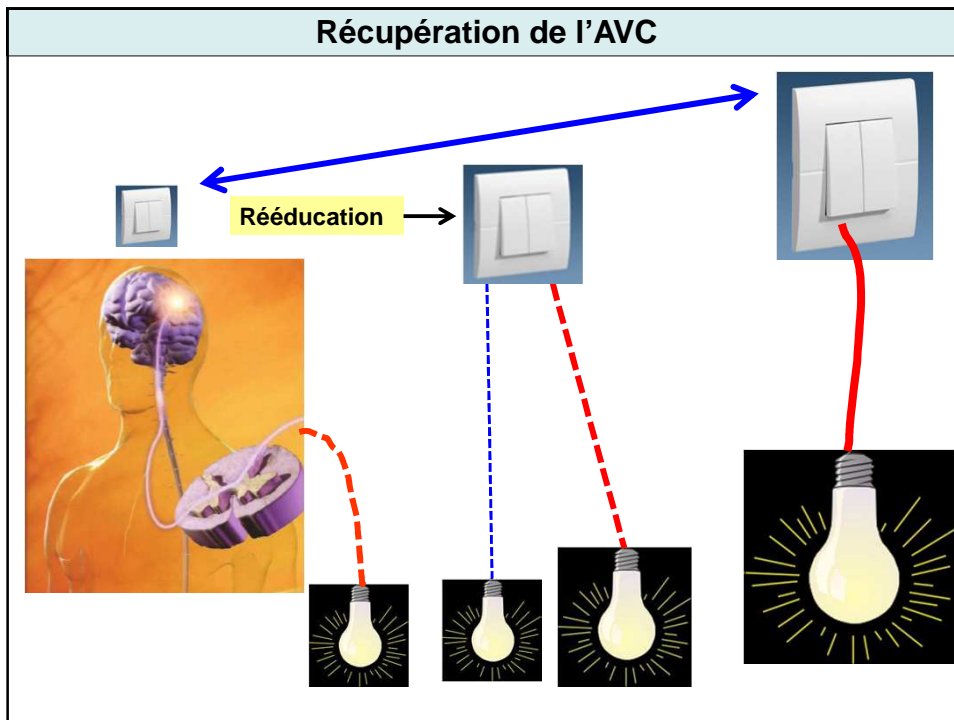
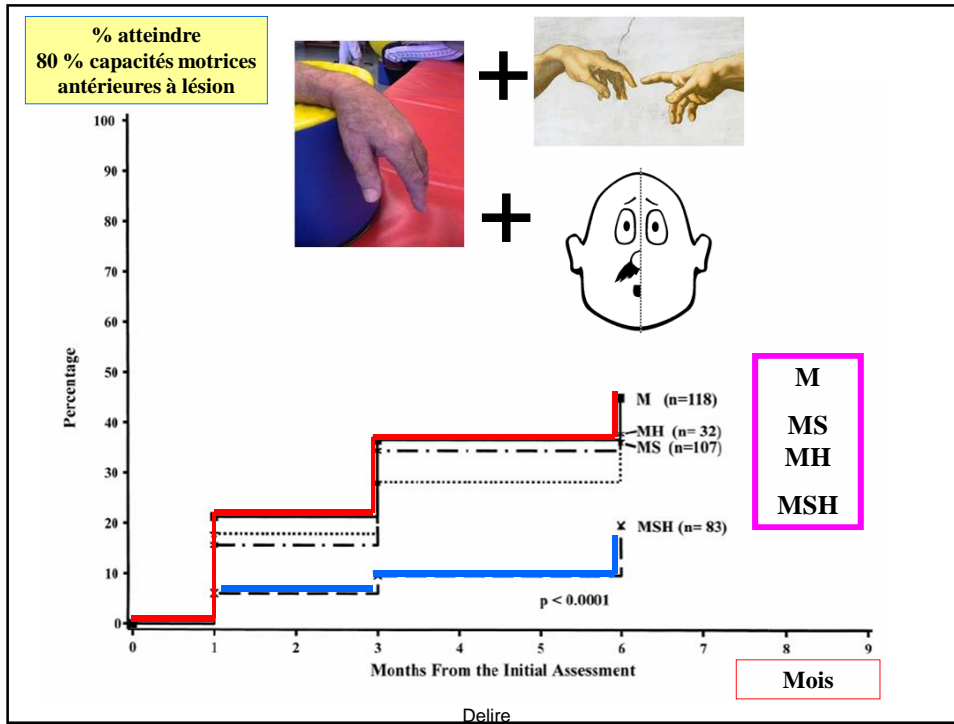
Participation active

Reposent sur la production de mouvement

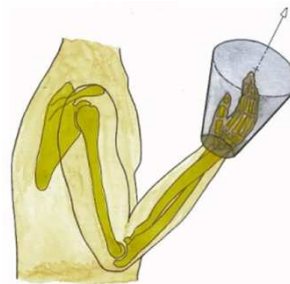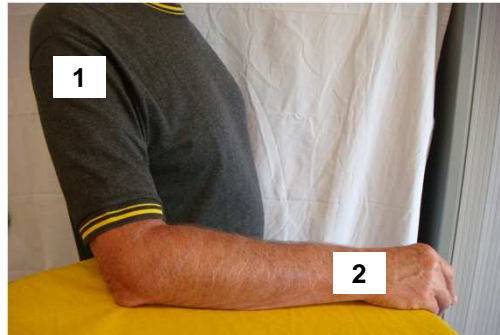
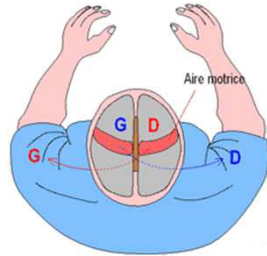


Actives

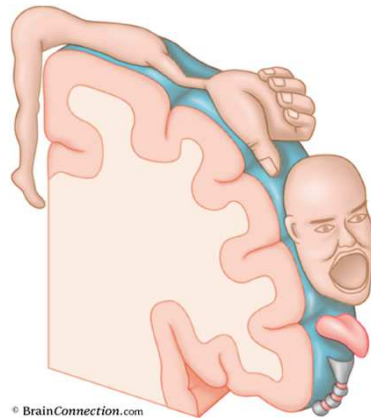
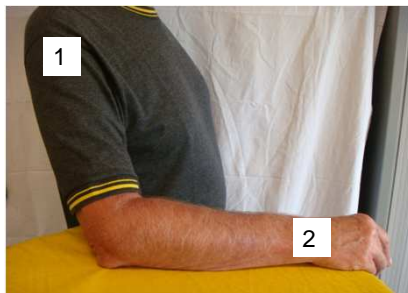




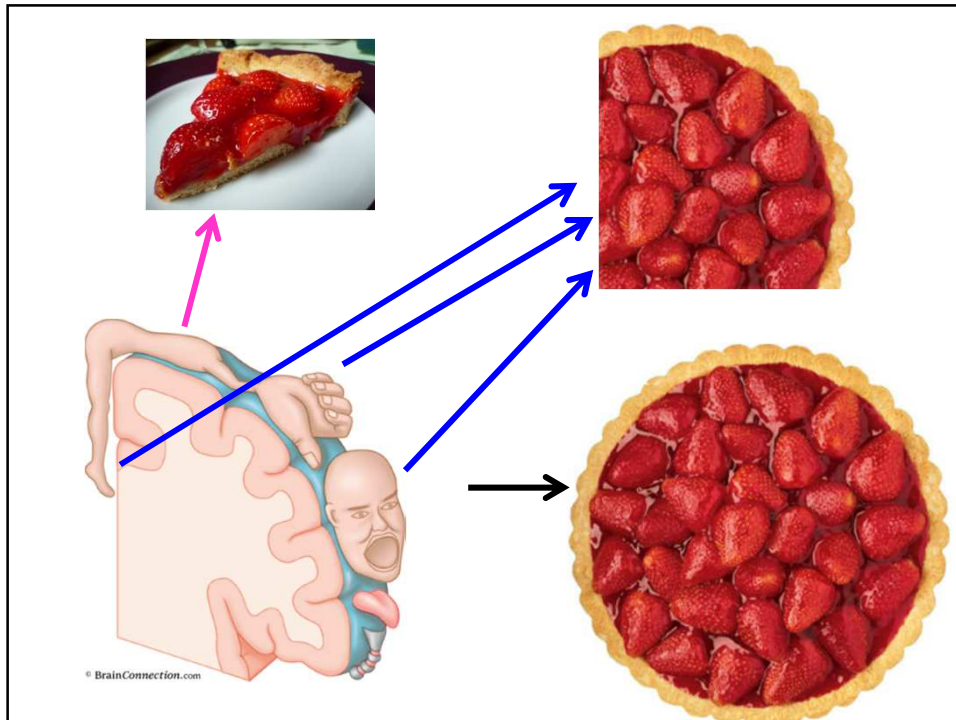
Récupération membre supérieur



Récupération épaule >>> main



Somatotopie
Anatomie
Contrôle neurologique
Compensation
Influence de la rééducation



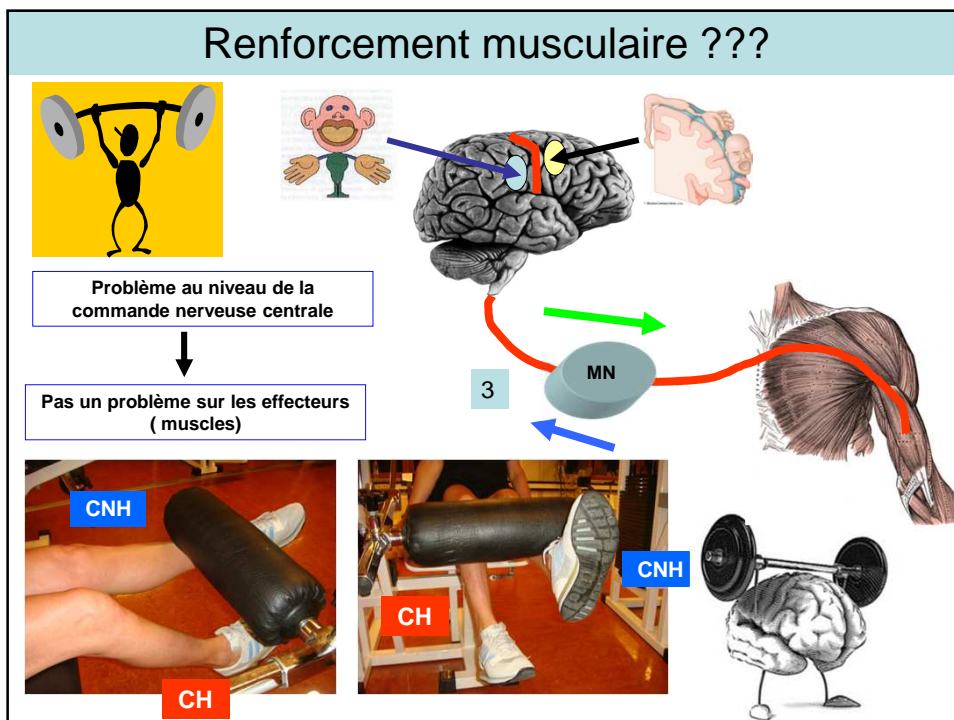
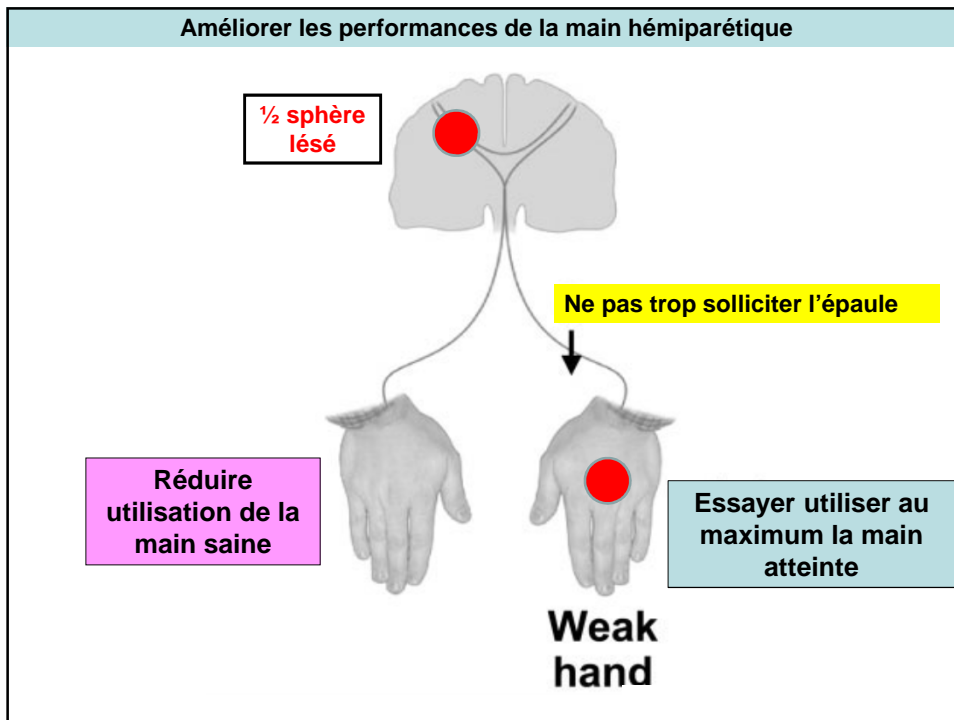
Récupération

Représentation motrice
Grand nombre de neurones si complexité de mouvement

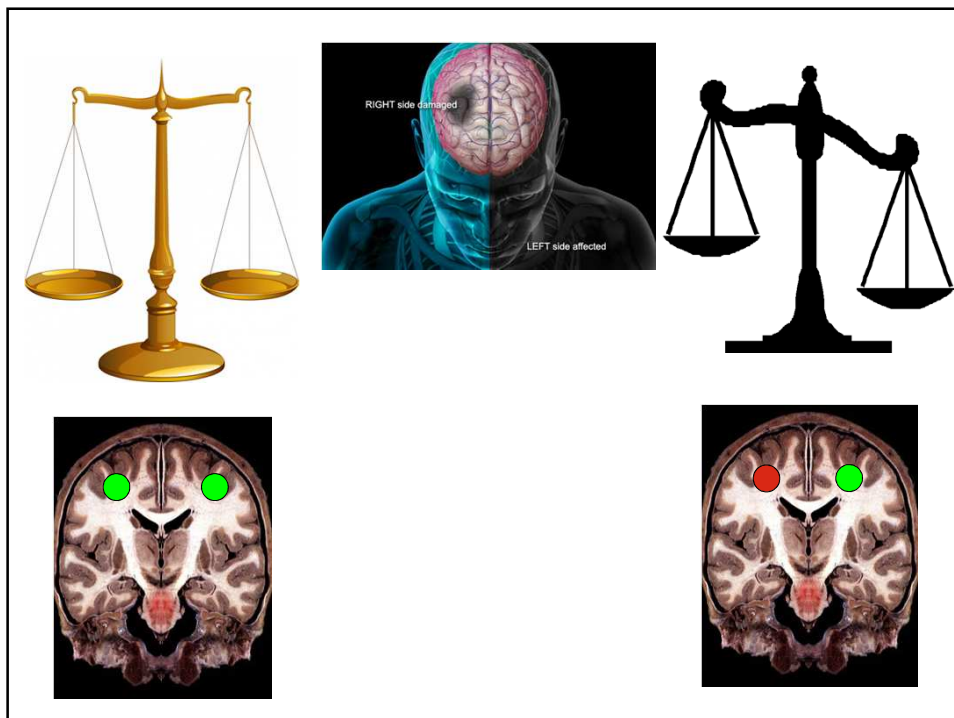
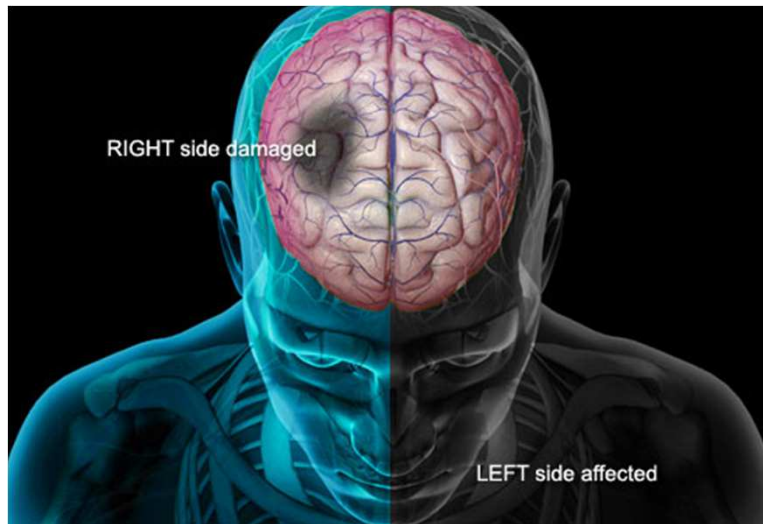
Récupération motrice
plus importante si mouvement peu complexe

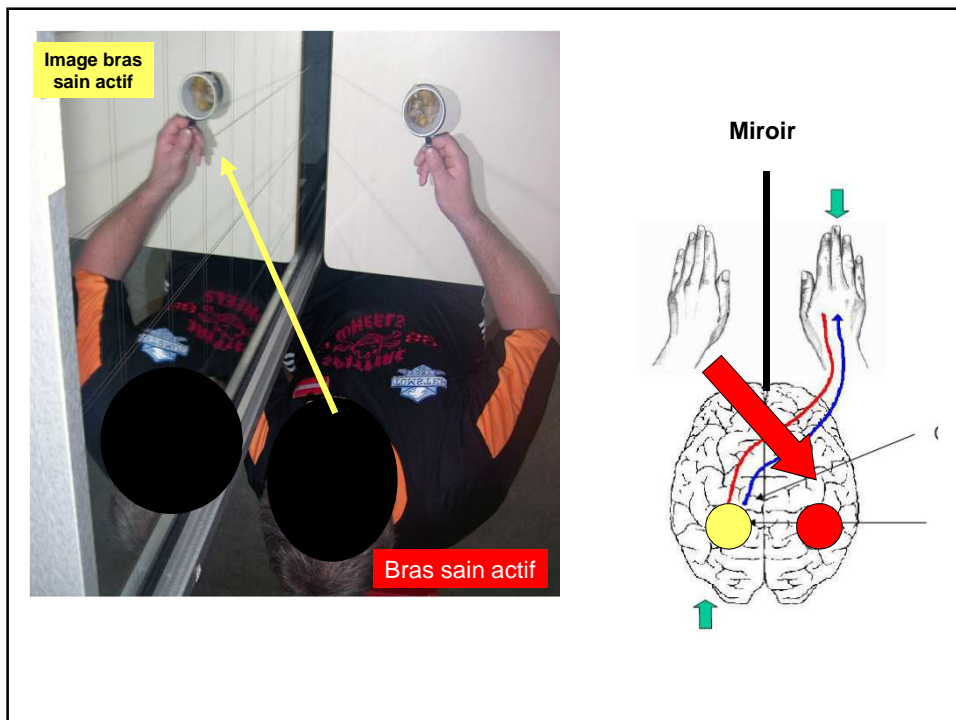
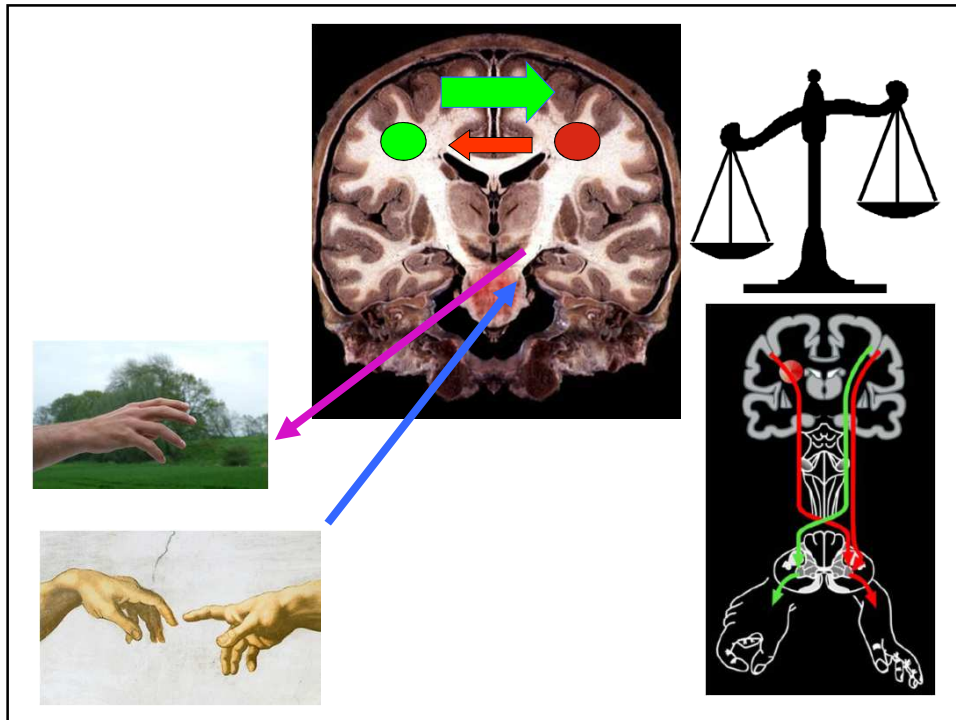
Récupération épaule et hanche >> main et pied

© BrainConnection.com



Rôle de l'hémisphère sain





Le caractère transitif ou intransitif de l'action observée

(Buccino et al. 2001)

Effecteur

Objet

42

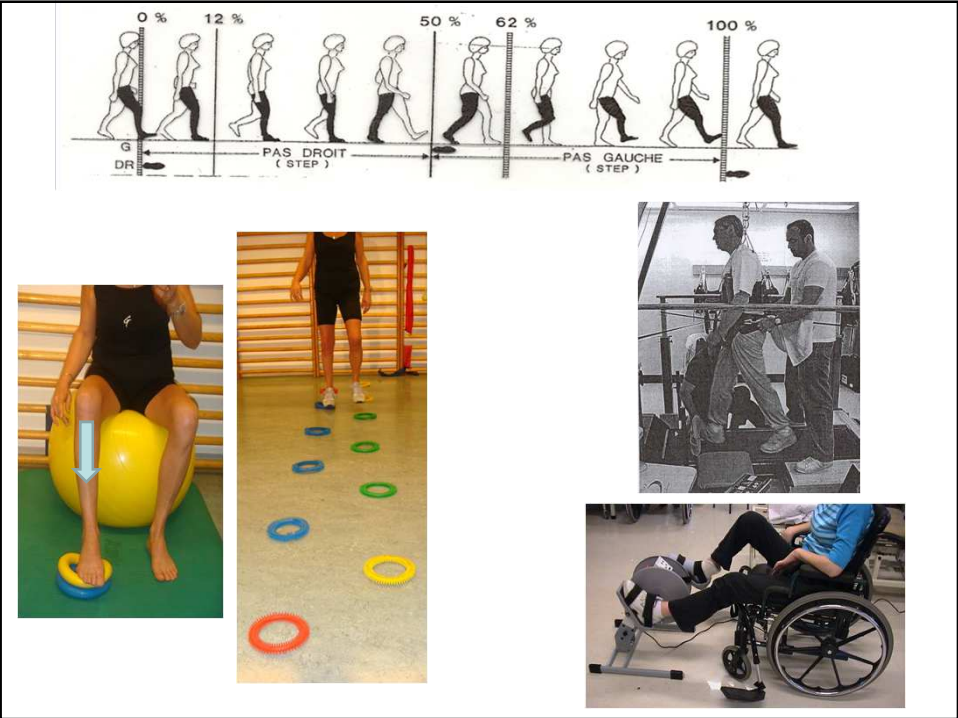
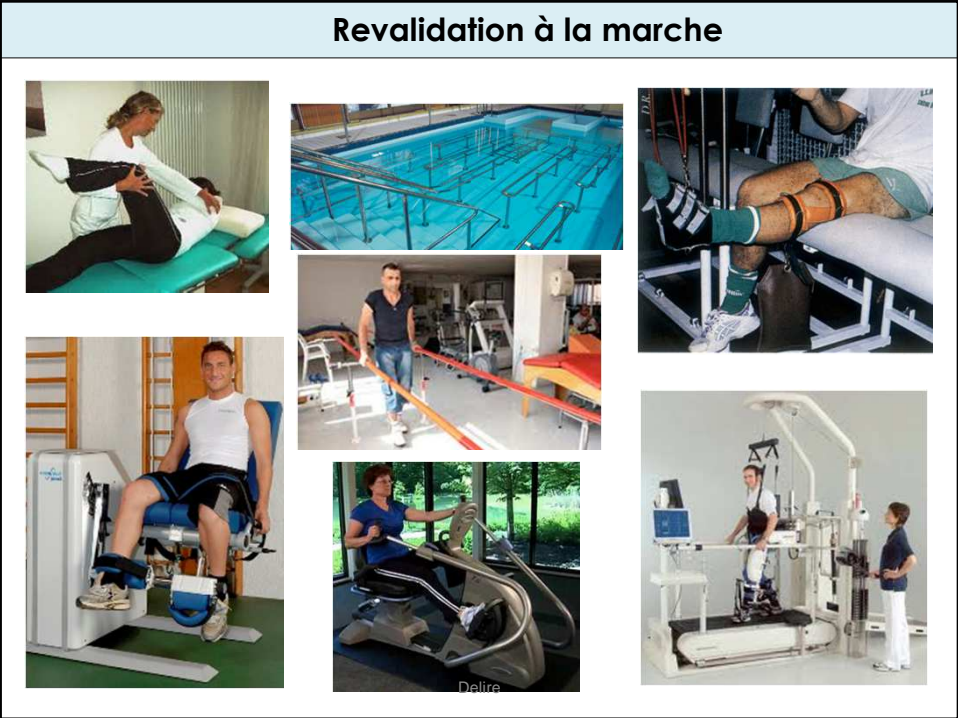Bloquer les segments corporels similaires au mouvement recherché côté atteint

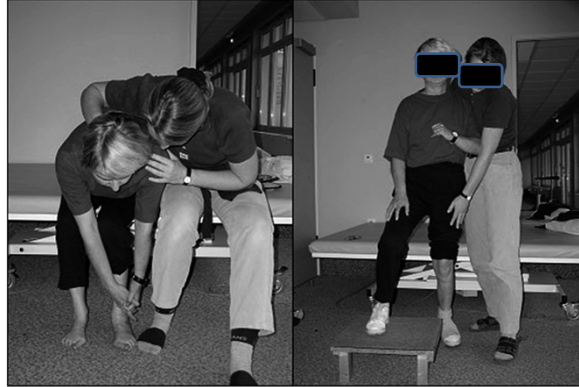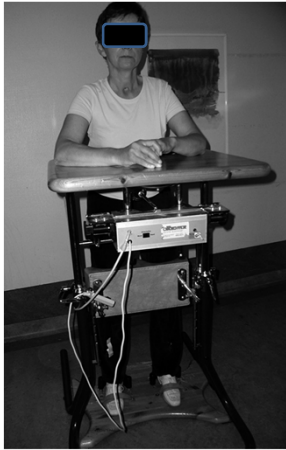
Kappa

Kappa

Kappa

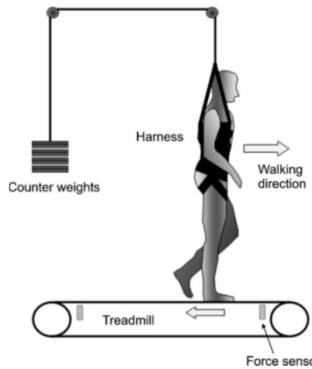
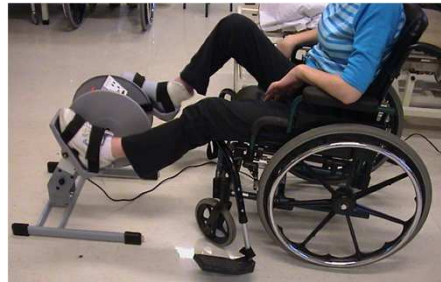Kappa







Modern concepts of motor learning, however, favor a task-specific repetitive training :
“The best way to improve walking is to walk.”

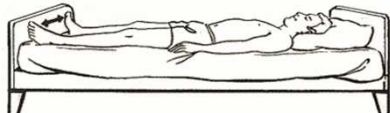


Activités cycliques


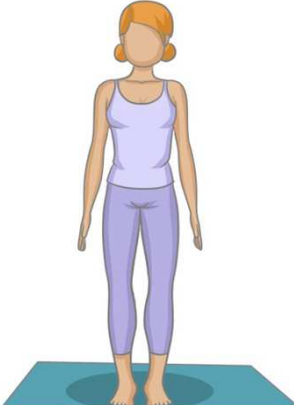


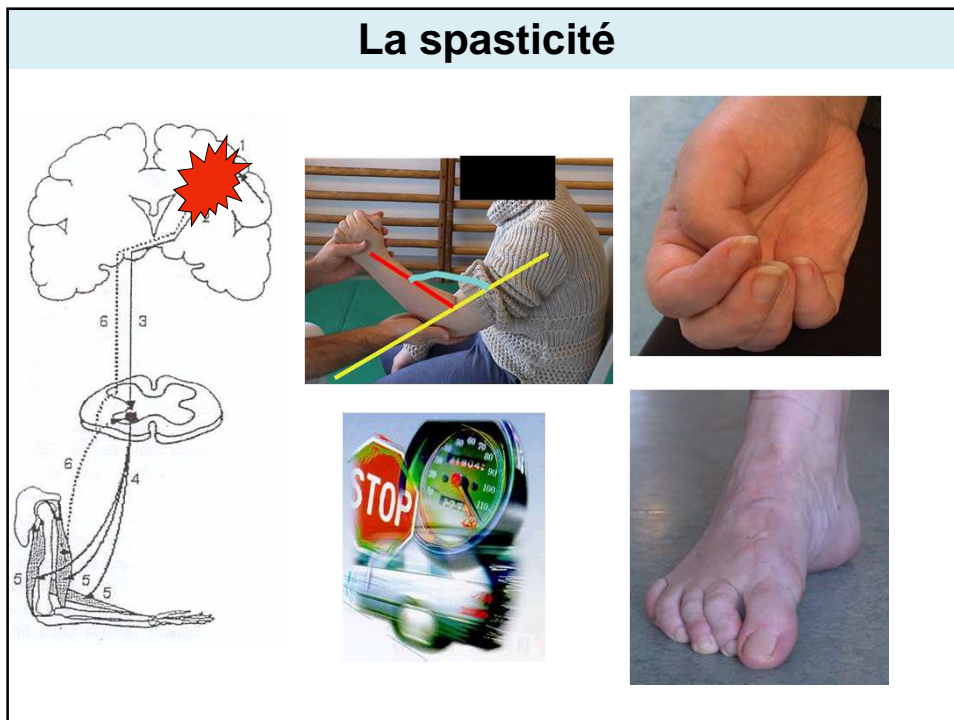

Qui peut le plus ... peut le moins

500 m	400 m	120 m	25 m
50 m	30 m	10 m	5 m





↓


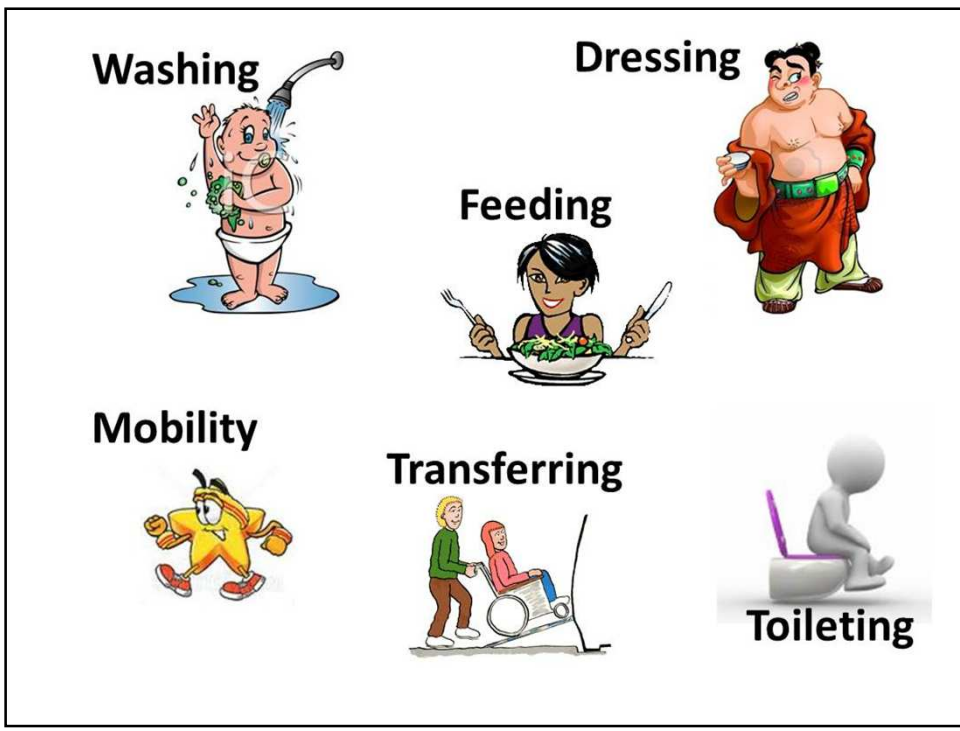


Stretching pour soulager les raideurs

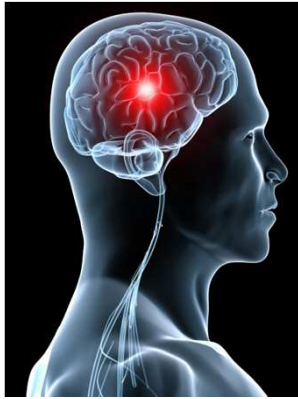

Activité en piscine





Conséquence de l'AVC = hémiplégie



Cérébrolésion

= lésion unilatérale (répercussions bilatérales)

= accident unique

= évolution « positive »

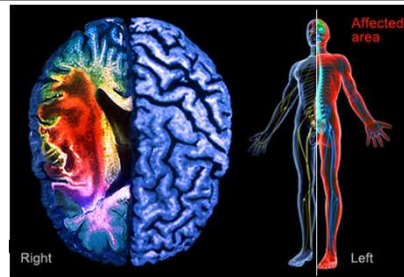
= dégâts corticaux et répercussions périphériques

= séquelles selon l'endroit de la lésion

= troubles du tonus (spasticité)

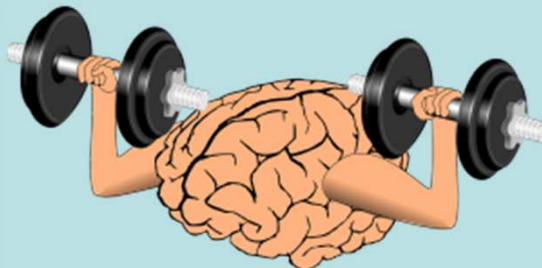
= troubles associés (mémoire, parole,...)

.....




Quelques « techniques » « efficaces »

Etre spécifique
à la tâche recherchée




Effet de l'entraînement non définitif

Répétition des séances (en continu ou par bloc)



Blötz a.s.b.l.
Lëtzebuerger Associatioun fir Betroffener vun engem Gehirnschlag



Blötz
a.s.b.l.

Delire Ralph	rdelire@ulb.ac.be
--------------	--